Case scenario 4
Clinical Breakout Session

Smallpox Vaccine Adverse Event Workshop

January 22-23, 2003

- Case Scenario 4
- A 32 y.o. male ER physician in a large southwestern state presents with an redness and swelling around his left eye 10 days after receiving smallpox vaccination. Periorbital edema is present with erythema, a few small pustules with slight ulceration are present on the upper eyelid close to the lid margin, the conjunctiva are not inflamed. The patient does not complain of eye pain and no corneal lesions are apparent. The patient's primary vaccination site shows a central pustule with 4 cm of surrounding erythema; the patient notes some pruritis and discomfort but says the lesion is beginning to improve.
- The patient relates that he has been keeping his bandage on the site with changes at the occupational health clinic except that when off work on days 5 and 6 after vaccination, he cleared brush on his ranch in very dusty conditions. During this period of time he had left his vaccination site unbandaged since he was not having any contact with other persons and he did not want sweat to cause maceration of the lesion. He does not wear contacts or glasses. The patient denies a history of 'fever blisters' or 'cold sores'.

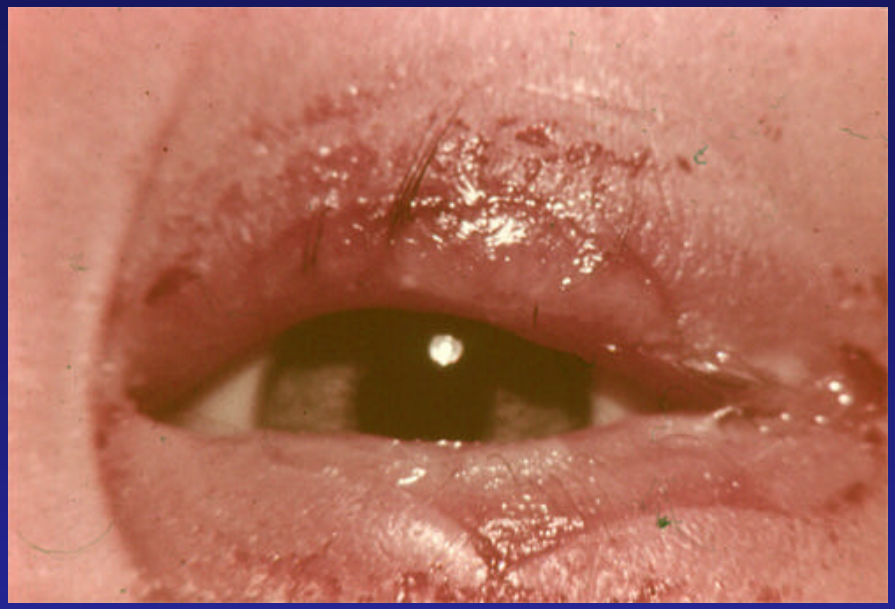

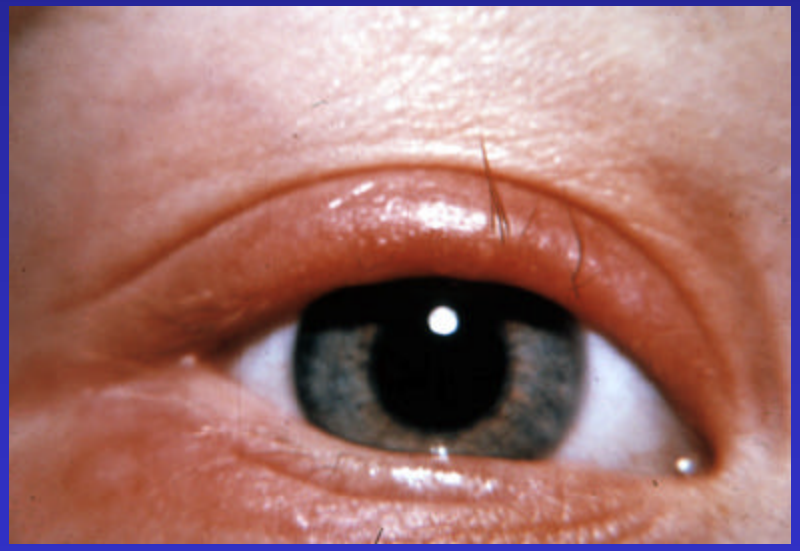

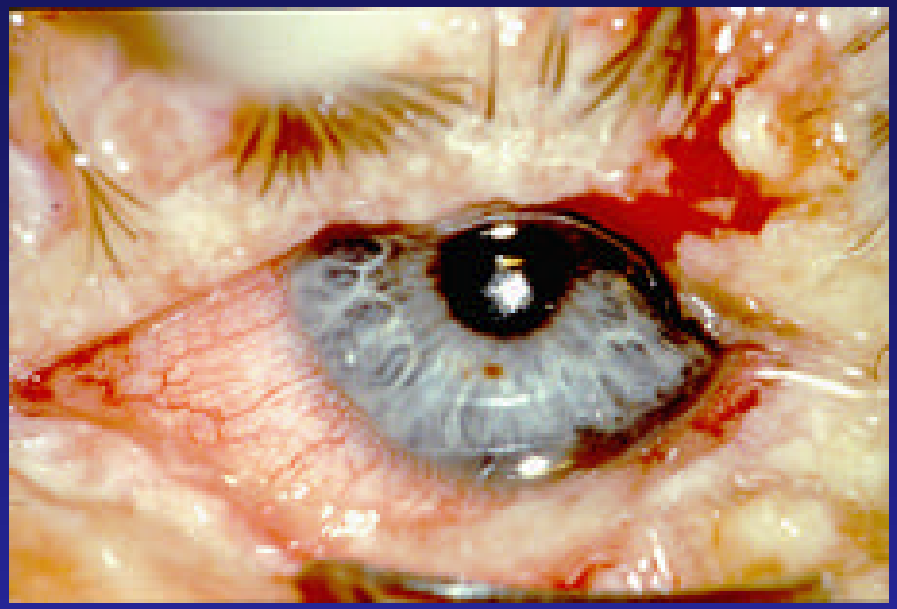

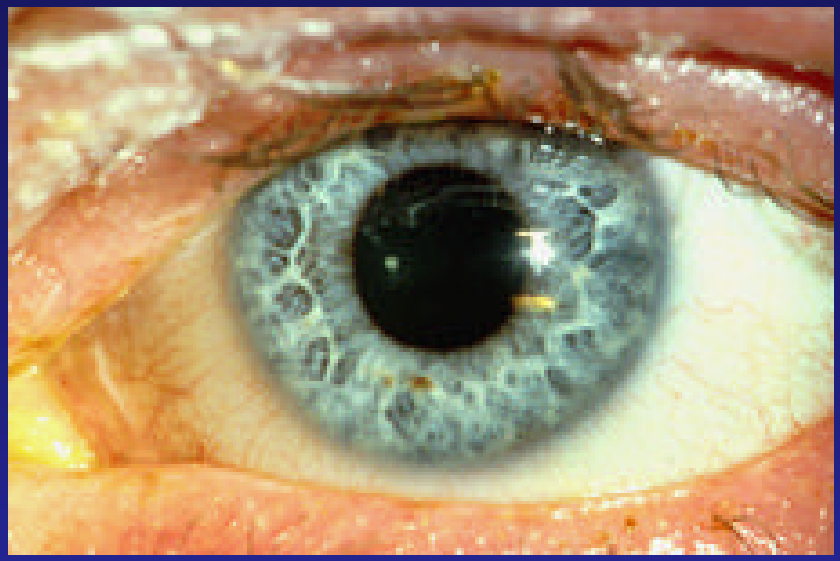

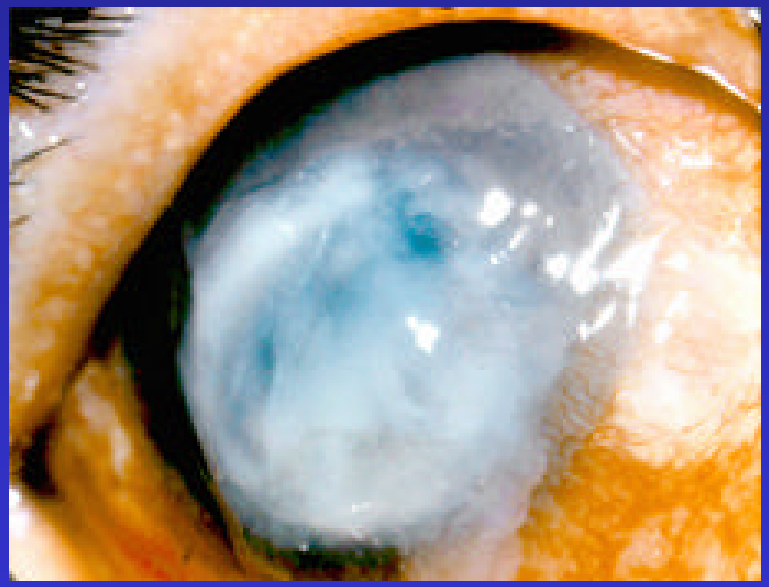

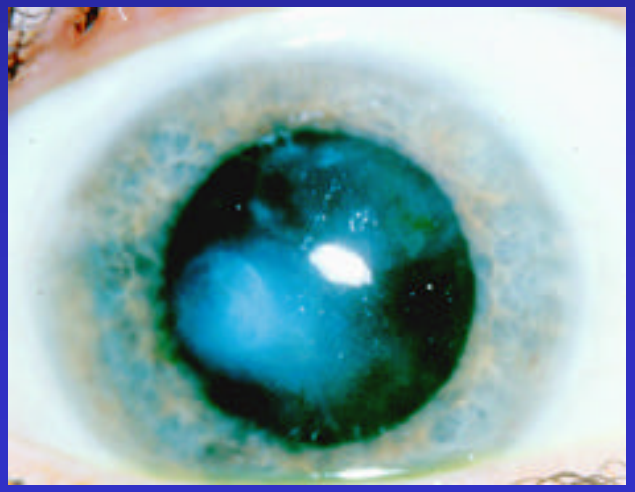

- 1. What is the most likely diagnosis?
- Inadvertent inoculation of the eye (ocular vaccinia). The presence of the ulcerated pustules with surrounding erythema and edema is very suspicious. This type of ocular involvement could be categorized as isolated blepharitis without conjunctivitis or keratitis.
- 2. Are there other conditions that should be considered?
- Other conditions that might cause a similar picture in this patient would include implantation (or reactivation) of herpes simplex virus (perhaps from contact with a patient's lesion) or allergic contact dermatitis from poison oak or ivy with the history of clearing brush. Some other conditions are listed on the clinical evaluation tool

- 3. What might a reasonable course of management for this patient?
- Topical antiviral prophylaxis should be considered and an ophthalmology consult should be obtained to assist in the management. While topical antivirals (trifluridine and vidarabine) are not FDA approved for treatment or prophylaxis of vaccinia, the product labels state that the drugs have in vitro and in vivo activity against vaccinia.
- 4. What is the usual course of the patient's condition?
- The evolution of the individual vaccinial lesions in inadvertent inoculation follows the course of normal smallpox vaccination lesions although anecdotally, ones that appear after day 5 tend to have a milder course.

- 5. If conjunctivitis and corneal lesions were present along with the blepharitis, how would suggested management differ?
- For vaccinial-induced blepharitis or conjunctivitis associated with keratitis, emergent ophthalmologic consultation and topical antiviral treatment would be recommended. VIG may be considered although data on the efficacy of VIG in ocular lesions is not available from controlled trials.
- 6. If isolated keratitis was present, would there be a difference in the suggested management?
- There is very limited older experimental data in a rabbit model that suggests that VIG may induce greater corneal opacity when used to treat vaccinial keratitis. If the patient had isolated keratitis, the use of VIG would not be recommended.

- 7. Do non-ocular inadvertent inoculations require specific anti-vaccinial treatment?
- VIG may be considered for other inadvertent inoculations where the lesions are severe, extensive, or painful. Inadvertent inoculations to areas of skin inflammation due to conditions such as allergic contact dermatitis are likely to be more widespread than inoculations into areas with intact skin.

Source: V. Folgnini MD

Source: Legical Images

Source: H. Kempe MD

- 1. What is the most likely diagnosis?
- Eczema vaccinatum due to contact with a smallpox vaccinee. The diagnosis of EV is supported by the vesiculo-pustular nature of the rash, the regionally extensive but not generalized nature of the rash, and by the history of active skin disease suggestive of atopic dermatitis.

- 2. What should be done immediately with the patient?
- The patient should be hospitalized for supportive care and a consultation with CDC should be consulted to request VIG. EV is associated with a high mortality rate; VIG can significantly reduce this mortality.

- 3. Should this patient be investigated for other medical conditions for diagnostic or prognostic purposes?
- Herpes simplex virus should be excluded as a cause of the rash as herpes can cause an identical rash in patients with atopic dermatitis and the patient is at increased risk for herpes simplex virus infection. Culture, antigen detection, or PCR techniques are likely to be available locally and should be utilized to exclude herpes.
- EV was not associated with identifiable immunodeficiencies in the past and an evaluation for immunodeficiency is not routinely recommended for patients with EV. However, this patient is at increased risk for HIV infection and it is reasonable that disorders of cell-mediated immunity may adversely affect the prognosis of EV.

- 4. What is the usual course of the patient's condition?
- The evolution of the individual vaccinial lesions in EV follows the course of normal smallpox vaccination lesions. Patients with extensive EV are frequently severely systemically ill. The clinical picture can resemble that of severe burn patients and these patients require close supportive care with attention to hemodynamic support, secondary infections, and skin care. High doses of IM VIG were frequently used in the past and repeated doses of VIG IV may be needed.
-

- 5. If CDC is consulted on this patient, what type of additional contact with CDC will occur?
- After VIG is administered to this patient, daily data on the patient's clinical condition and routine laboratory values are required under the IND. In cases where VIG is administered, the CDC clinical team (in conjunction with the state AE coordinators) will followup with the treating physician q 24 - 48 hours to assess the need for additional VIG until the patient improves.

- 6. What type of infection control measures are needed for this patient?
- The extensive lesions in EV contain large amounts of vaccinia virus. Nosocomial transmission has not been common but has occurred and is primarily linked to transmission via hands/objects in direct contact contact with the lesions. Standard precautions should greatly reduce the likelihood of transmission. CDC is working with HIP to develop a more detailed guidelines for infection control.

- 7. If this is a smallpox vaccine AE, can this case be linked to exposure to military personnel that departed city A on a naval convoy January 17?
- Usually EV in contacts presents 5 – 19 days after exposure. With an onset of ~ February 10, this case is unlikely to be linked to exposure prior to January 17.

- 8. Is there a spectrum of severity for this smallpox vaccine adverse event?
- Data from the U.K. in the 1960s suggests that milder forms of EV occur; a significant proportion of patients reported with the diagnosis of EV from dermatologists were not treated with VIG despite its availability. However, we do not have any data that would help us in firmly identifying which patients are likely to follow a milder course.

- 9. Would the presentation be different if a adult smallpox vaccinee or smallpox vaccinee adult contact has a history of similar skin rash in childhood but not as an adult?
- EV has occurred in both adults and children with a history of atopic dermatitis (or ‘eczema’) with either inactive or active disease at the time of exposure. Anecdotally, EV may be likely to be milder in individuals who have not had active skin disease since childhood.